

FISIOGRAFT

GEL - POWDER - SPONGE

A **synthetic biomaterial** used in dental and maxillofacial surgery to **fill bone cavities**, whether natural or pathological, based on hydroxyapatite and polyglycolic-polylactic acid (PLGA).

PLGA poly(lactic acid) and polyglycolic acid
Completely resorbable in 4-6 months



G Ghimas
D E N T A L

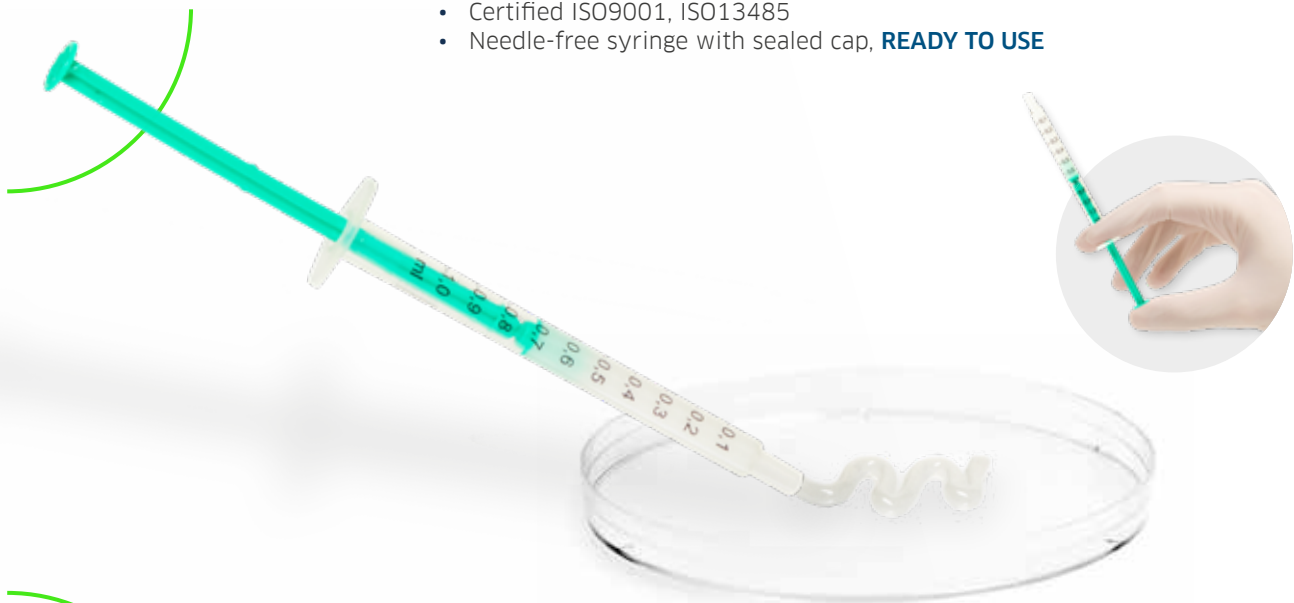FISIOGRAFT GEL



Completely resorbable in **4-6 MONTHS**

Physical form:
gel scaffold

- Composition: PLGA 20% (100 mg) + PEG 80% (400 mg)
- Package: 1 syringe 500 mg (Product code: PFOF0036)
- Package: 5 syringes 500 mg (Product code: PFOF0035)
- Medical Device CLASS III CE0426
- Certified ISO9001, ISO13485
- Needle-free syringe with sealed cap, **READY TO USE**



PLGA Gel

PLGA Gel

Trabecular porous structure accessible to the corpuscular part of the blood and GFs.

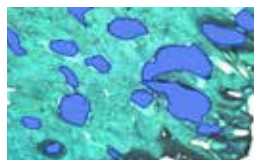


SEM PLGA magnification: 200X

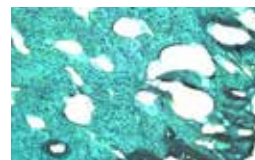


SEM PLGA magnification: 500X

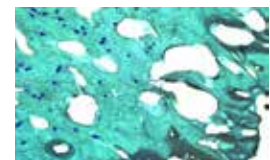
After six months, the histological examination of a core taken from a post-extraction site implanted with Fisiograft shows that: *'The material is fully resorbed and replaced by well-mineralised trabecular bone tissue containing bone marrow and has all the features of a normal alveolar bone.'*



Newly formed bone with medullary spaces



Newly formed bone with osteocytes



Newly formed bone with blood vessels

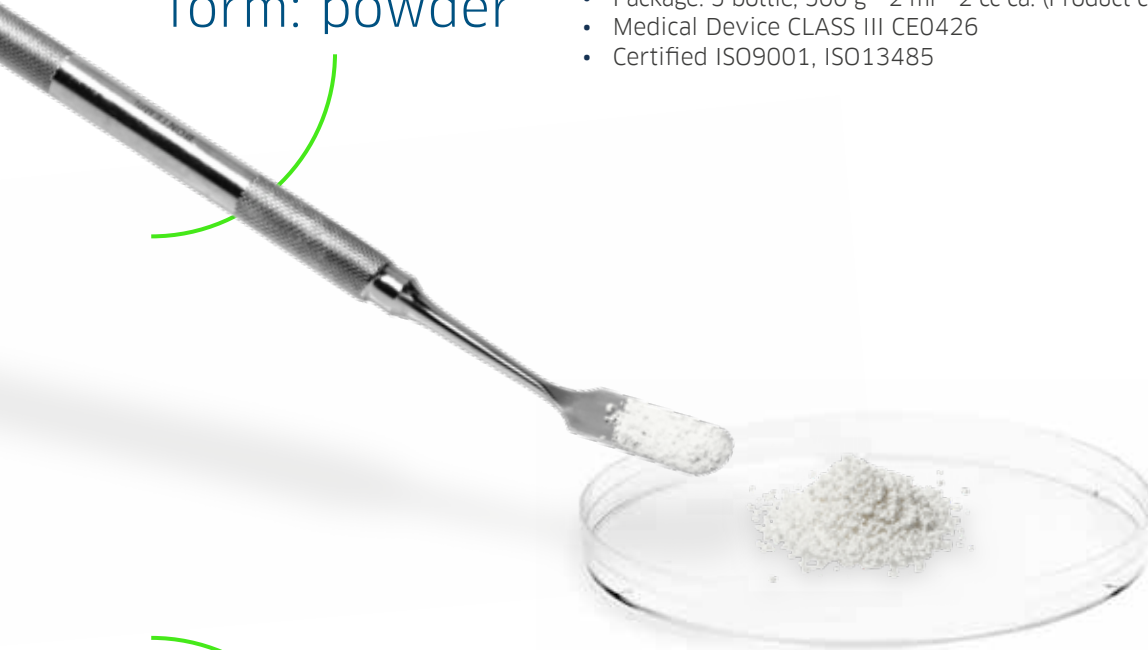FISIOGRAFT POWDER



Completely resorbable in **4-6 MONTHS**

Physical
form: powder

- Composition: PLGA 29% (145 mg) + DEXTRAN 71% (355 mg)
- Package: 1 bottle, 500 g - 2 ml - 2 cc ca. (Product code: PFOF0026)
- Package: 5 bottle, 500 g - 2 ml - 2 cc ca. (Product code: PFOF0025)
- Medical Device CLASS III CE0426
- Certified ISO9001, ISO13485



PLGA
lyophilised
powder

PLGA lyophilised powder

- Creates a larger number of access channels within it
- Is more easily traversed by blood
- Instant formation of a stable clot both inside and outside the material

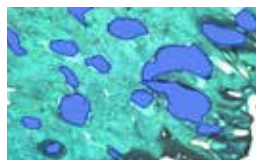


Fisiograft Powder Magnification: 200X

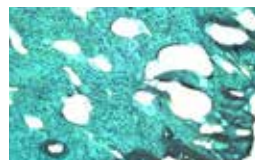


Fisiograft Powder Magnification: 500X

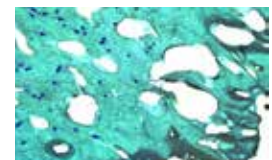
After six months, the histological examination of a core taken from a post-extraction site implanted with Fisiograft shows that: *'The material is fully resorbed and replaced by well-mineralised trabecular bone tissue containing bone marrow and has all the features of a normal alveolar bone.'*



Newly formed bone with medullary spaces



Newly formed bone with osteocytes



Newly formed bone with blood vessels

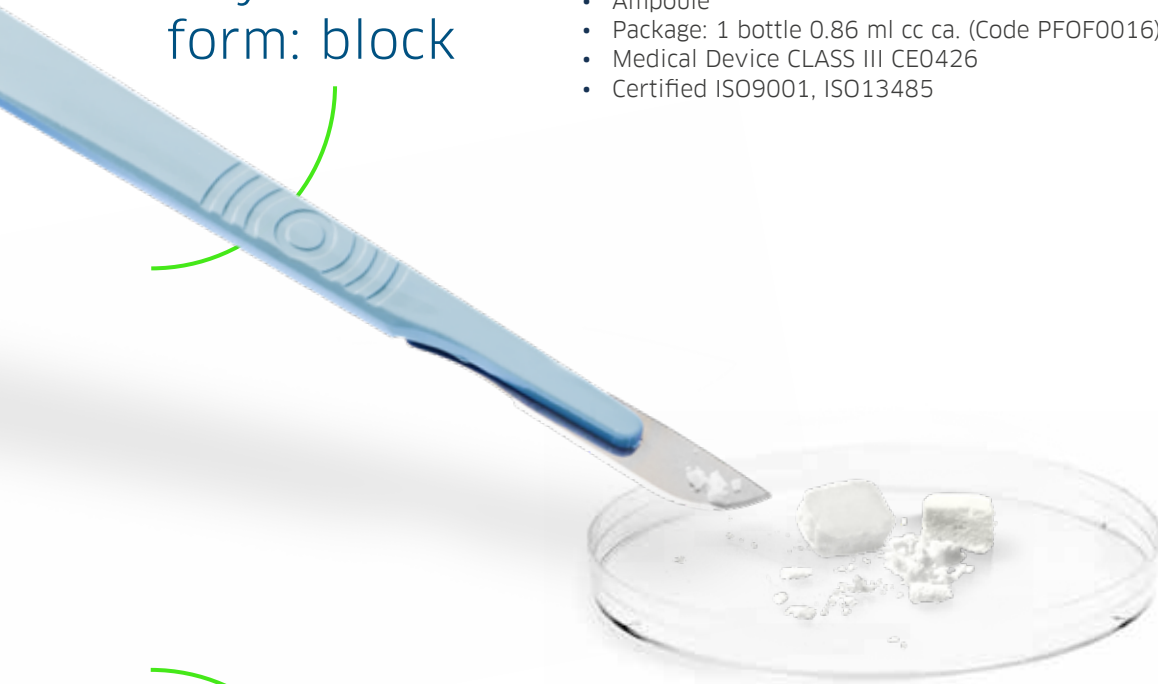FISIOGRAFT SPONGE

Completely resorbable in **4-6 MONTHS**



Physical
form: block


- Composition: PLGA 29% (156 mg) + PEG 71% (64 mg)
- Ampoule
- Package: 1 bottle 0.86 ml cc ca. (Code PFOF0016)
- Medical Device CLASS III CE0426
- Certified ISO9001, ISO13485



PLGA
lyophilised
sponge

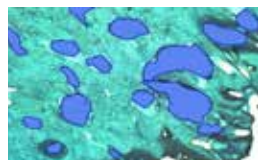
PLGA lyophilised sponge

- Creates a larger number of access channels within it
- Is more easily traversed by blood
- Instant formation of a stable clot both inside and outside the material

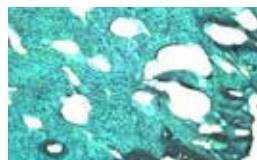

SEM Fisiograft Sponge magnification

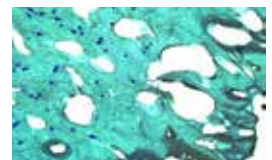
After six months, the histological examination of a core taken from a post-extraction site implanted with Fisiograft shows that: *'The material is fully resorbed and replaced by well-mineralised trabecular bone tissue containing bone marrow and has all the features of a normal alveolar bone.'*



Newly formed bone with medullary spaces



Newly formed bone with osteocytes



Newly formed bone with blood vessels

FISIOGRAFT
is the most
resorbable and
osteoconductive
biomaterial

“Biomateriali utilizzati in rigenerazione ossea: risultati istologici”

(Biomaterials used in bone regeneration: histological results)

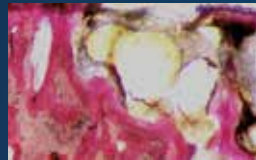
FISIOGRAFT was found to be the most resorbable and osteoconductive biomaterial 6-8 months after grafting.

	newly formed bone	medullary spaces	residue material
BIOCORAL	42%	40%	18%
BOVINE BONE	39%	34%	27%
BIOGLASS	40%	43%	17%
DFDBA	29%	37%	34%
FISIOGRAFT	43%	56%	1%
HYDROXYAPATITE	41%	30%	31%
AUTOLOGOUS BONE	42%	40%	18%
PEP-GEN P-15	40%	37%	23%
CALCIUM SULPHATE	48%	39%	13%

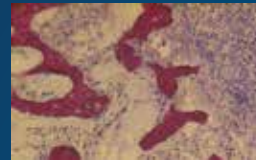Piattelli A. Implantologia-Orale (Oral implant dentistry). 2003; 4: 77-80

Complete bone neogenesis

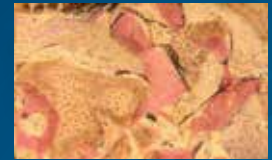These histological results confirm that FISIOGRAFT is an **“ideal space maintainer”**. Its centripetal and progressive erosion, up to its total degradation, in fact, allows bone tissue to be regenerated without interfering with the physiological repair processes.



Autologous bone



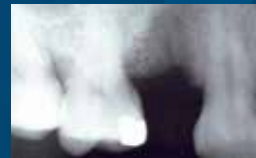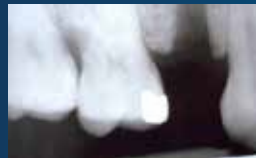FISIOGRAFT



Bovine bone

The newly formed bone can be checked with an X-ray

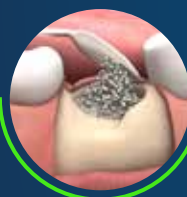Fisiograft is **NOT RADIOPAQUE** and enables bone neoformation to be checked with an X-ray.



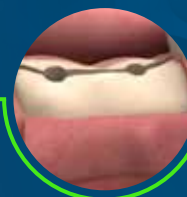
Applications



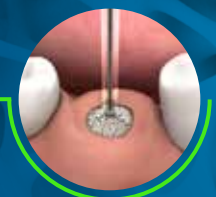Maxillary sinus elevation
FISIOGRAFT GEL
FISIOGRAFT POWDER + GEL
FISIOGRAFT SPONGE



Maintaining volume
FISIOGRAFT SPONGE
FISIOGRAFT POWDER
FISIOGRAFT POWDER + GEL



Split crest
FISIOGRAFT POWDER
FISIOGRAFT POWDER + GEL
FISIOGRAFT SPONGE



Post-extraction
FISIOGRAFT SPONGE
FISIOGRAFT POWDER + GEL

The **ADVANTAGES** of **FISIOGRAFT**

GEL

- ✓ Fully reabsorbed within **4 - 6 MONTHS**
- ✓ Fully replaced by **NEWLY FORMED MINERALISED CELLULAR BONE**
- ✓ **NO ODDS RATIO:** BSE - HIV - HBV - SARS
- ✓ **NON-RADIOPAQUE**
- ✓ **HIGH BIOCOMPATIBILITY**
- ✓ **EASILY ADHERES** to irregular cavity walls

POWDER

- ✓ Fully reabsorbed within **4 - 6 MONTHS**
The molecular weight allows for rapid biological degradation
- ✓ **FULLY REPLACED** by newly formed mineralised cellular bone
- ✓ **NO ODDS RATIO:** BSE - HIV - HBV - SARS
- ✓ **NON-RADIOPAQUE**
- ✓ **HIGH BIOCOMPATIBILITY**
- ✓ It **FULLY OCCUPIES** irregular cavities

SPONGE

- ✓ Fully reabsorbed within **4 - 6 MONTHS**
Its molecular weight allows for rapid biological degradation
- ✓ **FULLY REPLACED** by newly formed mineralised cellular bone
- ✓ **NO ODDS RATIO:** BSE - HIV - HBV - SARS
- ✓ **NON-RADIOPAQUE**
- ✓ **HIGH BIOCOMPATIBILITY**
- ✓ When hydrated with **FISIOGRAFT GEL**, saline solution or blood, the sponge can be put in the receiving site without compacting it
- ✓ If inserted into post-extraction alveoli, Fisiograft Sponge **REDUCES ALVEOLAR RIDGE RESORPTION**

FISIOGRAFT: MORE THAN **100 PUBLICATIONS**

BIBLIOGRAPHY

- 1 - Bone regeneration strategies: Engineered scaffolds, bioactive molecules and stem cells current stage and future perspectives. AntalyaHo-Shui-Ling et al., Biomaterials Volume 180, October 2018, Pages 143-162.
- 2 - Poly(Lactic-co-Glycolic Acid): Applications and Future Prospects for Periodontal Tissue Regeneration Xiaoyu Sun, Chun Xu, Gang Wu, Qingsong Ye and Changning Wang. Academic Editor: Patrick van Rijn Received: 11 April 2017; Accepted: 11 May 2017; Published: 1 June 2017.
- 3 - Stem cells, growth factors and scaffolds in craniofacial regenerative medicine. Viktor Tollemar et al. Genes & Diseases Volume 3, Issue 1, March 2016, Pages 56-71.
- 4 - Effects of lactic acid and glycolic acid on human osteoblasts; a way to understand PLGA involvement in PLGA/calcium phosphate composite failure. Florent Meyer, John Wardale, Serena Best, Ruth Cameron, Neil Rushton, Roger Brooks 2012 Jun;30(6):864-71.
- 5 - Valutazione dell'uso di un biomateriale nel trattamento dei difetti parodontali infraossei. (Evaluation of the use of a biomaterial in the treatment of intrabony periodontal defects). Briguglio F, Isola G, Lapi M, Briguglio R, Briguglio E. Italian Oral Surgery 2009; 8 (5): 247-55.
- 6 - Alveolar bone dimensional changes of post-extraction sockets in humans: a systematic review. Van der Weijden F, Dell'Acqua F, Slot DE. J Clin Periodontol 2009; 36: 1048-1058.
- 7 - Polylactide/polyglycolide copolymer in bone defect healing in humans. Bertoldi C, Zaffe D, Consolo U. Biomaterials 2008; 29: 1817-23.
- 8 - Maxillary sinus augmentation with different biomaterials: a comparative histologic and histomorphometric study in man. Scarano A, Degidi M, Iezzi G, Pecora G, Piattelli M, Orsini G, Caputi S, Perrotti V, Mangano C, Piattelli A. Implant Dent. 2006; 15 (2): 197-207.
- 9 - Histological study on sinus lift grafting by Fisiograft and Bio-Oss. Zaffe D, Leghissa GC, Pradelli J, Botticelli AR. J Mater Sci: Mater Med 2005; 16: 789-93.
- 10 - Guided Tissue Regeneration with a Synthetic Co-polymer of Polyglycolic and Polylactic Acid (Fisiograft® gel) in Fenestrations and/or Dehiscences Defects Around Implants: A Clinical Controlled Study at 1 Year. Rocchietta I, Piloni A, Rasperini G, Simion M. Poster Presentation Abstracts the 19th Annual meeting of the Academy of Osseointegration 03/2004; P118.
- 11 - Ridge preservation following tooth extraction using a polylactide and polyglycolide sponge as space filler: a clinical and histological study in man. Serino G, Biancu S, Iezzi G, Piattelli A. Clin Oral Impl. Res. 2003; 14: 651-58.
- 12 - Use of PLA-PGA as a bone filler: clinical experience and histologic study of a case. Stancari F, Zanni B, Bernardi F, Calandriello M, Salvatorelli G. Quintessenz (Germany) 2000; 51

