

FISIOGRAFT

SLURRY GEL

An invasive **medical device** used in dental and maxillofacial surgery to **fill bone cavities**, whether natural or pathological, based on polylactic acid and polyglycolic acid (PLGA).

PLGA polylactic acid and polyglycolic acid
Completely resorbable in 4-6 months

**ONE
FOR
ALL**

To be used alone or mixed with:

- + AUTOGRAFT
- + ALLOGRAFT
- + XENOGRAFT
- + SYNTHETIC



G Ghimas
D E N T A L

FISIOGRAFT SLURRY GEL

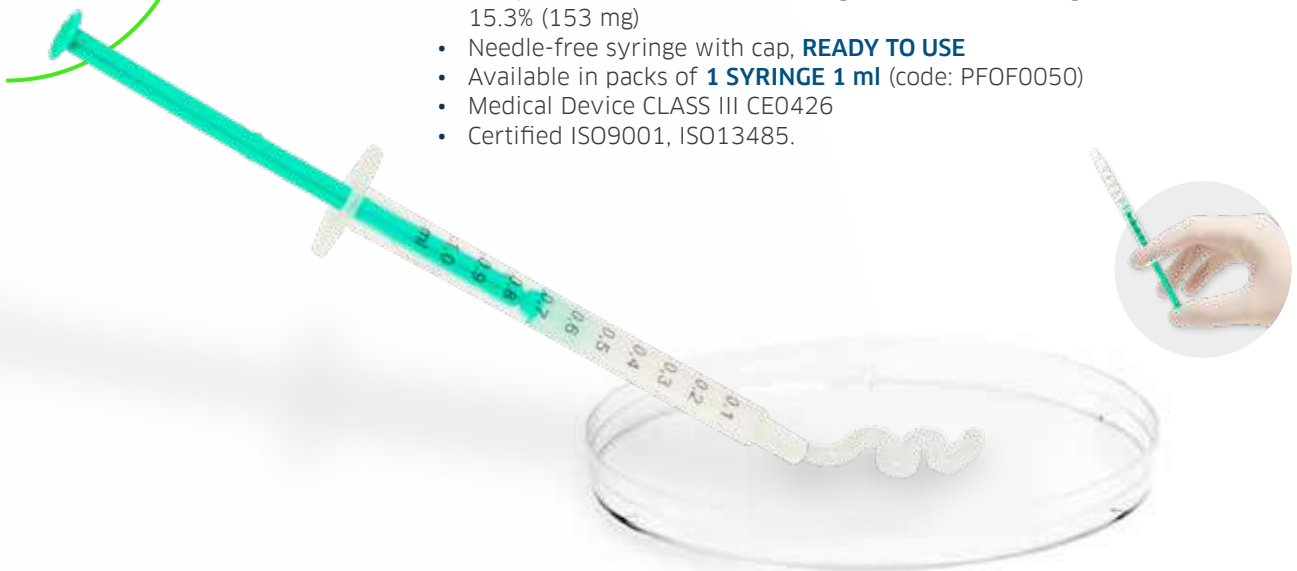


Completely resorbable in **4-6 MONTHS**

Physical form: gel

The structure of **SLURRY** is characterised by a microdispersion of solids in a gel. It consists of solid polymers, which are unable to settle in a hydrophilic liquid environment, thus giving rise to a **homogeneous gelled fluid**. Once applied, the liquid component is quickly removed from the product, which allows the solid microstructure of the copolymer to form the **blood-permeable supporting reticulum**.

- Composition: PLGA 25.7% (257 mg) + PEG 59% (590 mg) + DEXTRAN 15.3% (153 mg)
- Needle-free syringe with cap, **READY TO USE**
- Available in packs of **1 SYRINGE 1 ml** (code: PFOF0050)
- Medical Device CLASS III CE0426
- Certified ISO9001, ISO13485.



PLGA Slurry Gel

PLGA

Trabecular porous structure accessible to the corpuscular part of the blood and GFs.

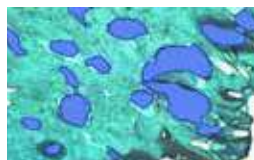


SEM PLGA magnification: 200X

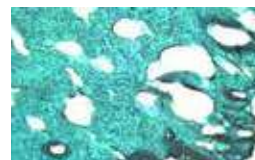

SEM PLGA magnification: 500X

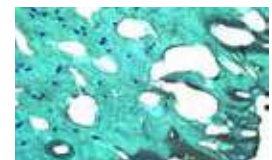After six months, the histological examination of a core taken from a post-extraction site implanted with Fisiograft shows that: *'The material is fully resorbed and replaced by well-mineralised trabecular bone tissue containing bone marrow and has all the features of a normal alveolar bone.'*



Newly formed bone with medullary spaces



Newly formed bone with osteocytes



Newly formed bone with blood vessels

ONE FOR ALL

FISIOGRAFT is the most resorbable and osteoconductive biomaterial

“Biomateriali utilizzati in rigenerazione ossea: risultati istologici”

(Biomaterials used in bone regeneration: histological results).

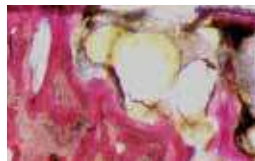
FISIOGRAFT was found to be the most resorbable and osteoconductive biomaterial 6-8 months after grafting.

	newly formed bone	medullary spaces	residue material
BIOCORAL	42%	40%	18%
BOVINE BONE	39%	34%	27%
BIOGLASS	40%	43%	17%
DFDBA	29%	37%	34%
FISIOGRAFT	43%	56%	1%
HYDROXYAPATITE	41%	30%	31%
AUTOLOGOUS BONE	42%	40%	18%
PEP-GEN P-15	40%	37%	23%
CALCIUM SULPHATE	48%	39%	13%

Piattelli A. Implantologia-Orale (Oral implant dentistry). 2003; 4: 77-80

Complete bone neogenesis

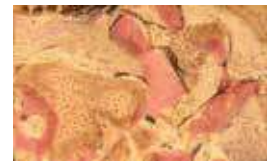These histological results confirm that FISIOGRAFT is an **“ideal space maintainer”**. Its centripetal and progressive erosion, up to its total degradation, in fact, allows bone tissue to be regenerated without interfering with the physiological repair processes.



Autologous bone



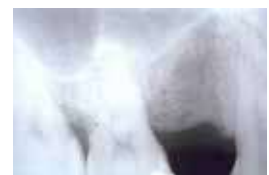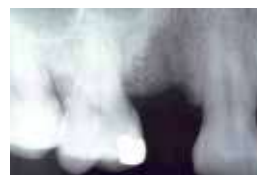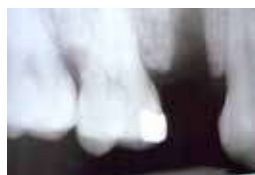FISIOGRAFT



Bovine bone

The newly formed bone can be checked with an X-ray

Fisiograft is **NOT RADIOPAQUE** and enables to check the bone neoformation with an X-ray.



The **ADVANTAGES** of **FISIOGRAFT SLURRY GEL**

- ✓ Fully reabsorbed within **4 - 6 MONTHS**
- ✓ Fully replaced by **NEWLY FORMED MINERALISED CELLULAR BONE**
- ✓ **NO ODDS RATIO:** BSE - HIV - HBV - SARS
- ✓ **NON-RADIOPAQUE**
- ✓ **HIGH BIOCOMPATIBILITY:** Slurry is highly biocompatible due to the nature of the polymers it is composed of. In fact, PLGA undergoes enzymatic degradation, while dextran undergoes the normal metabolic process of sugars
- ✓ **PLASTICITY:** this special physical characteristic ensures optimal filling, even in the most inaccessible sites
- ✓ **EASILY ADHERES** to irregular cavity walls

APPLICATION IN CONJUNCTION WITH OTHER BIOMATERIALS

Fisiograft Slurry Gel can be regarded as an ideal support for all types of granular inserts of synthetic and non-synthetic nature.

- It makes the granular derivative plastic, which makes it easy to insert into any application site.
- Adds support through the PLGA scaffold.
- It will be used as a space maintainer and will be completely reabsorbed within 4-6 months.
- It makes it possible to use even small amounts of autologous material, providing a volumising effect and promoting tissue regeneration.



**ONE
FOR
ALL**

To be used alone or mixed with:

- + **AUTOGRAFT**
- + **ALLOGRAFT**
- + **XENOGRAFT**
- + **SYNTHETIC**

FISIOGRAFT: MORE THAN **100 PUBLICATIONS**

BIBLIOGRAPHY

- 1 - Bone regeneration strategies: Engineered scaffolds, bioactive molecules and stem cells current stage and future perspectives. AntalyaHo-Shui-Ling et al., Biomaterials Volume 180, October 2018, Pages 143-162.
- 2 - Poly (Lactic-co-Glycolic Acid): Applications and Future Prospects for Periodontal Tissue Regeneration Xiaoyu Sun, Chun Xu, Gang Wu, Qingsong Ye and Changning Wang. Academic Editor: Patrick van Rijn Received: 11 April 2017; Accepted: 11 May 2017; Published: 1 June 2017.
- 3 - Stem cells, growth factors and scaffolds in craniofacial regenerative medicine. Viktor Tollema et al. Genes & Diseases Volume 3, Issue 1, March 2016, Pages 56-71.
- 4 - Effects of lactic acid and glycolic acid on human osteoblasts: a way to understand PLGA involvement in PLGA/calcium phosphate composite failure. Florent Meyer, John Wardale, Serena Best, Ruth Cameron, Neil Rushton, Roger Brooks 2012 Jun;30(6):864-71.
- 5 - Valutazione dell'uso di un biomateriale nel trattamento dei difetti parodontali infraossei. (Evaluation of the use of a biomaterial in the treatment of intrabony periodontal defects). Briguglio F, Isola G, Lapi M, Briguglio R, Briguglio E. Italian Oral Surgery 2009; 8 (5): 247-55.
- 6 - Alveolar bone dimensional changes of post-extraction sockets in humans: a systematic review. Van der Weijden F, Dell'Acqua F, Slot DE. J Clin Periodontol 2009; 36: 1048-1058.
- 7 - Polylactide/polyglycolide copolymer in bone defect healing in humans. Bertoldi C, Zaffe D, Consolo U. Biomaterials 2008; 29: 1817-23.
- 8 - Maxillary sinus augmentation with different biomaterials: a comparative histologic and histomorphometric study in man. Scarano A, Degidi M, Iezzi G, Pecora G, Piattelli M, Orsini G, Caputi S, Perrotti V, Mangano C, Piattelli A. Implant Dent. 2006; 15 (2): 197-207.
- 9 - Histological study on sinus lift grafting by Fisiograft and Bio-Oss. Zaffe D, Leghissa GC, Pradelli J, Botticelli AR. J Mater Sci: Mater Med 2005; 16: 789-93.
- 10 - Guided Tissue Regeneration with a Synthetic Co-polymer of Polyglycolic and Polylactic Acid (Fisiograft® gel) in Fenestrations and/or Dehiscences Defects Around Implants: A Clinical Controlled Study at 1 Year. Rocchietta I, Pilloni A, Rasperini G, Simion M. Poster Presentation Abstracts the 19th Annual meeting of the Academy of Osseointegration 03/2004; P118.
- 11 - Ridge preservation following tooth extraction using a polylactide and polyglycolide sponge as space filler: a clinical and histological study in man. Serino G, Biancu S, Iezzi G, Piattelli A. Clin Oral Impl. Res. 2003; 14: 651-58.
- 12 - Use of PLA-PGA as a bone filler: clinical experience and histologic study of a case. Stancari F, Zanni B, Bernardi F, Calandriello M, Salvatorelli G. Quintessenz (Germany) 2000; 51.

